

REVIEW ARTICLE

Lmax and imiquimod 3.75%: the new standard in AK management

E. Stockfleth*

Klinik für Dermatologie, Venerologie und Allergologie, St. Josef-Hospital, Ruhr-Universität Bochum, Bochum, Germany

*Correspondence: E. Stockfleth. E-mail: e.stockfleth@klinikum-bochum.de

Abstract

The new target for the treatment of actinic keratosis (AK) is the detection and clearance of clinical and subclinical lesions across an entire sun-exposed field. This is because patients with AK have field cancerization as ultraviolet light affects the entire sun-exposed area and because it is not possible to predict which AK lesions will progress into invasive squamous cell carcinoma. To fully assess the effectiveness of field-directed therapies against the full burden of AK, a new efficacy concept has been developed which is based on the reduction in lesions from Lmax, or the maximum lesion count during treatment. This new parameter enables the efficacy of a field-directed therapy against both clinical and subclinical lesions to be assessed. Imiquimod 3.75% is a novel field-directed therapy which uniquely can detect and clear both clinical and subclinical lesions across a large sun-exposed field such as the full face or balding scalp, and so far is the only AK treatment to have had its efficacy assessed with the Lmax concept. The detection of subclinical lesions is evidenced by an increase in lesion count during each of the 2-week treatment cycles, which are separated by a 2-week treatment-free interval. The median percentage reduction in lesions from Lmax with imiquimod 3.75% is 92%, and the effective clearance of both clinical and subclinical lesions leads to sustained lesion clearance for at least 1 year. Imiquimod 3.75% has an acceptable tolerability profile. Rest periods from treatment may be taken if required to manage local skin reactions, with no loss in efficacy. In conclusion, Lmax and imiquimod 3.75% together set the new standard in the management of patients with AK.

Received: 4 September 2014; Accepted: 6 October 2014

Conflict of interest

ES has a consultant contract with Meda, Almirall, Galderma, Medigene, LEO and Novartis.

Funding source

This supplement was funded by Meda Pharma GmbH & Co. KG.

Introduction

Actinic keratosis (AK) lesions represent part of a disease continuum which can progress from initial subclinical disease into invasive squamous cell carcinoma (SCC) with the potential to metastasize.^{1–4} Chronic exposure to ultraviolet light is a key risk factor in the development of AK.^{5,6} This causes neoplastic changes across the entire area of sun-exposed skin leading to field cancerization.⁷ As a consequence, both visible clinical lesions and invisible subclinical lesions coexist in the field of sun-exposed skin.^{7–9} Any of these lesions can progress into invasive SCC with the risk of disease progression rising as the number of lesions increases.¹⁰ Because it is not possible to accurately predict which lesions will undergo the transformation to invasive disease,¹¹ the new target for the treatment of AK is to detect and eliminate the full burden of disease

(including both clinical and subclinical lesions) across an entire sun-exposed field without any limitation in the size of the field that can be treated.^{1,12}

This article has two main objectives. The first objective was to introduce Lmax (the maximum lesion count during treatment) as the new standard parameter for assessing the efficacy of field-directed AK therapy as it takes into account the clearance of both clinical and subclinical lesions. The second objective was to introduce imiquimod 3.75% as the new standard treatment for AK. This therapy is uniquely able to detect and clear both clinical and subclinical lesions across an entire sun-exposed field as assessed with the new Lmax concept. Indeed, imiquimod 3.75% allows dermatologists to simply detect and clear subclinical lesions without the need for expensive and complicated imaging technology.

Lmax: the new standard for assessing the efficacy of field-directed AK therapy

Traditional efficacy parameters, which compare the number of clinical lesions at the start and end of treatment, do not assess whether AK therapies are able to treat the full burden of disease. This is because the detection and clearance of subclinical lesions is not taken into consideration. Consequently, traditional efficacy parameters underestimate the real efficacy of field-directed AK therapies that can detect and eliminate subclinical lesions in addition to clearing clinical lesions.

Recognizing that AK consists of both clinical and subclinical lesions, a group of leading dermatologists recently introduced Lmax, the maximum lesion count during treatment, as the new standard efficacy parameter for assessing the efficacy of field-directed AK therapies.¹³ Lmax itself evaluates the full burden of disease because it is the sum of clinical lesions together with subclinical lesions which become detectable during treatment. Lmax can occur at any time point during treatment. The reduction in lesions from Lmax assesses the ability of a field-directed therapy to clear the full burden of disease, i.e. both clinical and subclinical lesions, and so represents a complete and accurate assessment of the efficacy of an AK treatment. The new Lmax parameter and traditional efficacy parameters are compared in Table 1.

The Lmax concept is illustrated in Fig. 1 for a patient treated with imiquimod 3.75% (see next section). This patient had 12 AK lesions at baseline increasing to an Lmax of 30 during the first treatment cycle as imiquimod 3.75% unmasked subclinical lesions which were previously invisible. Four weeks after treatment, there were no lesions remaining and no further lesions appeared by the end of the study. Consequently, this patient had a reduction in 30 AK lesions from Lmax to the end of follow-up. In comparison, there was a reduction in 12 AK lesions from baseline to the end of follow-up, i.e. a difference of 18 lesions between measuring efficacy from baseline vs. from Lmax. This highlights that the reduction in lesions from Lmax represents a complete measure of the efficacy of an AK treatment, whereas traditional efficacy parameters underestimate the efficacy of AK treatments.

Imiquimod 3.75%: the new standard in AK management

Imiquimod 3.75% represents a breakthrough in the management of AK, as it is the only AK treatment which can detect and clear both clinical and subclinical lesions and which can be used to treat an entire sun-exposed field such as the full face or

balding scalp.^{13–17} These are key advantages over other field-directed therapies which are not able to detect and treat all types of AK lesions and/or can only be applied to restricted areas of skin.^{18–26} In addition, imiquimod 3.75% is to date the only AK therapy which has had its efficacy assessed with the Lmax concept.¹³ The treatment regimen for imiquimod 3.75% involves up to two sachets of medication being applied to the entire affected area once-daily before bedtime for two 2-week treatment cycles separated by a compulsory 2-week treatment-free period.^{14,15} Rest periods from treatment are permitted, if necessary, to allow local skin reactions to be managed.¹⁴

Mechanism of action

Imiquimod is an immune response modifier which acts as a toll-like receptor 7 agonist.²⁷ It induces the production of various pro-inflammatory cytokines including interferon α , tumour necrosis factor- α and interleukins 1, 6, 8, 10 and 12 from Langerhans cells, monocytes, macrophages and dendritic cells.^{28,29} These cytokines stimulate both the innate and acquired immune pathways leading to enhancement of both antiviral and antitumour activity.^{28,30} The mode of action of imiquimod also involves stimulation of apoptosis in skin cancer cells, and increased expression of genes activating natural killer cells, macrophages and dendritic cells.^{31,32}

The immune response generated as a result of imiquimod treatment is directed against both clinical and subclinical lesions. The response against the subclinical lesions causes these lesions to become visible leading to a transient increase in lesion count during treatment with imiquimod (Fig. 1).^{8,9,13,14,16} The immune response can also lead to local skin reactions, and these, in particular erythema, are an indication of the pharmacodynamic effects of imiquimod and demonstrate that a localized immune response in the epidermis has begun.^{7,16} In other words, they are a sign that the drug is treating the disease. Currently, there is no published evidence that other AK treatments can detect and treat subclinical lesions, so this represents a distinctive feature of the clinical profile of imiquimod.

Efficacy results with imiquimod 3.75% and Lmax

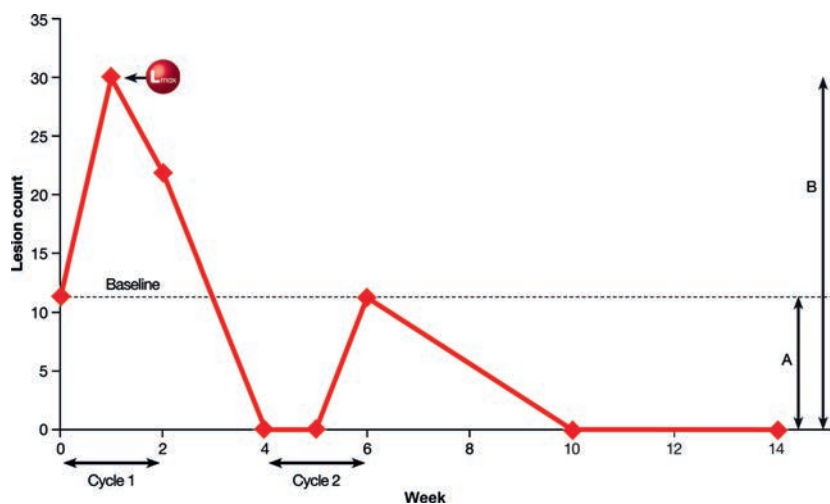
The efficacy data with imiquimod 3.75% demonstrate that it is able to address the full burden of disease (i.e. clinical and subclinical lesions) across a large area of sun-exposed skin such as the full face or balding scalp. The data from two pivotal, 14-week, placebo-controlled, double-blind studies of imiquimod

Table 1 Comparison of Lmax and traditional efficacy parameters

	Lmax	Traditional efficacy endpoints
Measurement	Reduction in lesions from Lmax to end of study	Reduction in lesions from baseline to end of study
AK lesion types evaluated	Clinical AND subclinical	Clinical only
Implications	Complete and accurate assessment of field-directed AK therapy	Underestimate the efficacy of field-directed therapy as subclinical lesions are not considered

Lmax, maximum lesion count during treatment.

Figure 1 Case study of patient treated with imiquimod 3.75% in two 2-week treatment cycles illustrating Lmax concept and need for two treatment cycles.³⁶ Baseline = 12 lesions, Lmax = 30 lesions. (A) Reduction in lesions from baseline = 12; (B) Reduction in lesions from Lmax = 30. Lmax, maximum lesion count during treatment.



3.75% were analysed using the reduction in lesion counts from Lmax to assess its real efficacy against both clinical and subclinical lesions.¹³ In these studies, 160 patients were randomized to treatment with imiquimod 3.75% and 159 were randomized to placebo. Patients in both groups had a median of 10 AK lesions at baseline. Patients self-applied study medication to the full face or balding scalp in two 2-week treatment cycles separated by a 2-week treatment-free interval.

The pooled efficacy data over time showed that there was a transient increase in lesion count during both cycles of treatment. During the first treatment cycle, the median number of lesions nearly doubled, whereas there was a smaller increase during the second treatment cycle. The median value for Lmax was 22 for the imiquimod 3.75% group and 13 for the placebo group. The transient increase in lesion count during each treatment cycle corresponds to the detection or unmasking of subclinical lesions which were not previously visible in the cancerous field.⁷⁻⁹ This demonstrates the ability of imiquimod 3.75% to detect subclinical lesions without the need for sophisticated imaging technology. At the end of the studies, 8 weeks after the last application of treatment, the median number of lesions in the imiquimod 3.75% group had decreased to two.¹³

Applying the Lmax concept to these data demonstrated that the median percentage reduction in all AK lesions (including both clinical and subclinical lesions) from Lmax to the end of the studies was 92.2% (Table 2). In terms of absolute lesion reduction, a median of 18 AK lesions were cleared with imiquimod 3.75% to the end of follow-up. Both the median percentage reduction and the median absolute lesion reduction from Lmax to the end of follow-up were significantly greater with imiquimod 3.75% compared with placebo ($P < 0.0001$; Table 2).¹³

Comparing the reduction in lesions from Lmax in the pivotal imiquimod 3.75% studies with the reduction in lesions from baseline highlights the underestimation of the efficacy of field-directed AK treatments with traditional efficacy parameters as

they do not take into account the clearance of subclinical lesions. As shown in Table 2, the median absolute reduction in lesions from baseline with imiquimod 3.75% was 7, whereas the median absolute reduction in lesions from Lmax was 18, i.e. a difference of 11 lesions. Similarly, the median percentage reduction in lesions from baseline was 81.8% compared with 92.2% from Lmax.¹³ This demonstrates that the real efficacy of AK treatments can only be measured using the reduction in lesions from Lmax, as this evaluates their ability to clear both clinical and subclinical lesions.

The efficacy of imiquimod 3.75%, assessed with the reduction in lesions from Lmax, was shown to be sustained through one additional year of follow-up.³³ Forty-two patients with no lesions at the end of the two pivotal double-blind studies of imiquimod 3.75% entered a 12-month follow-up period.³⁴ In this population, the median number of baseline lesions was 9 and the median value for Lmax was 22. At the end of the 12-month follow-up period (i.e. 14 months after the last dose of imiquimod 3.75%), the median absolute reduction in lesions from Lmax was 19, and the median percentage reduction in lesions from Lmax was 97.2%.³³ This sustained long-term lesion clearance with imiquimod 3.75% is due to its ability to clear both clinical and subclinical lesions across a large treated sun-exposed field such as the full face or balding scalp.

The reduction in lesions from Lmax with imiquimod 3.75% currently represents the best efficacy results of any field-directed therapy. Furthermore, these data confirm Lmax as a new concept which can reliably assess the real efficacy of a field-directed AK therapy by taking into account not only the clearance of clinical lesions across a large treated sun-exposed field but also the subclinical lesions which become evident during treatment.

Detection of actual invasive SCC risk

A key advantage of treatment with imiquimod 3.75% compared with other AK therapies is that it enables the visualization of

Table 2 Comparison of efficacy parameters for field-directed AK treatments: results from pivotal clinical studies of imiquimod 3.75% vs. placebo

	Traditional efficacy endpoints: From baseline to EOS ¹⁶		Field cancerization variables: From Lmax to EOS ¹³	
	Imiquimod 3.75% (n = 160)	Placebo (n = 159)	Imiquimod 3.75% (n = 160)	Placebo (n = 159)
Median % reduction	81.8%*	25.0%	92.2%*	39.3%
Median absolute reduction	7.0*†	2.0†	18.0*	5.0

* $P < 0.0001$ imiquimod 3.75% vs. placebo.

†Data on file, Meda.

AK, actinic keratosis; EOS, end of study; Lmax, maximum lesion count during treatment.

subclinical lesions across a large treated sun-exposed field. In doing so, imiquimod 3.75% reveals a patient's full burden of disease and allows their actual risk of developing invasive SCC to be more closely and accurately monitored. A patient's risk of progressing to invasive SCC is typically estimated from the number of clinical AK lesions, with the risk increasing with greater numbers of lesions.¹⁰ A study in an Australian population indicated that patients with 1–5 AK lesions had a 2-fold increased risk of developing SCC compared to people with no lesions. Patients with 6–20 AK lesions had a 4-fold increased SCC risk and those with over 20 AK lesions had an 11-fold increased SCC risk.¹⁰ However, in addition to the clinical AK lesions, the sun-exposed skin surrounding these lesions also contains multiple subclinical or invisible lesions, which also may contribute to a patient's risk of developing invasive SCC.⁷

The visualization of the full AK burden and SCC risk with imiquimod 3.75% is illustrated in two patient case studies shown in Fig. 2.³⁵ Patient 1 had a low initial AK lesion count of 5 lesions and may therefore be considered at low risk of progressing to invasive SCC. However, during the first cycle of treatment with imiquimod 3.75%, the number of lesions increased by

220% to 16. This latter number of lesions suggests that this patient's real risk of developing invasive SCC was much greater than indicated by their baseline number of clinical lesions.³⁵ Although Patient 2 had 20 AK lesions at baseline and therefore was known to be at high risk of developing invasive SCC, the number of clinically visible AK lesions at baseline only indicated a fraction of this patient's disease burden and actual risk of progressing to invasive SCC. During the first treatment cycle, a further 20 lesions appeared suggesting that this patient's risk of developing invasive SCC was even higher than originally anticipated.³⁵ In both of these patients, there was a $\geq 90\%$ reduction in lesions from Lmax to the end of follow-up, emphasizing the efficacy of imiquimod 3.75% in patients with different disease severities.

Overall, these case studies illustrate the ability of imiquimod 3.75% to detect subclinical lesions and reveal a patient's full burden of disease. They also show that by effectively clearing clinical and subclinical lesions across large sun-exposed fields, imiquimod 3.75% has the potential to reduce the risk of invasive SCC in high-risk patients and those who erroneously appear to have a lower risk when only the visible lesions are taken into account.³⁵

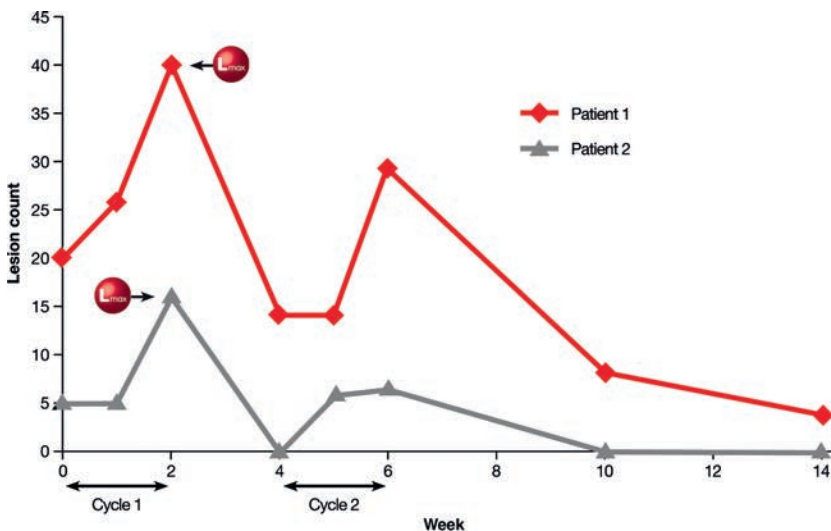


Figure 2 Case studies of patients with low and high baseline AK lesion counts treated with imiquimod 3.75% in two 2-week treatment cycles.³⁵ Lmax, maximum lesion count during treatment.

Importance of two treatment cycles

To ensure optimal clearance of all of a patient's AK lesions, including both clinical and subclinical lesions, two cycles of treatment with imiquimod 3.75% are essential. This is illustrated with the data from the patient case study shown in Fig. 1.³⁶ This patient had 12 clinical AK lesions at baseline. During the first 2-week treatment cycle, a further 18 AK lesions became evident as imiquimod 3.75% unmasked previously invisible subclinical lesions leading to an Lmax of 30.³⁶ By the end of the 2-week treatment-free interval, there were no visible AK lesions and the patient appeared macroscopically cleared of disease. However, by the end of the second 2-week treatment cycle, 12 lesions had become apparent and these were cleared 4 weeks later with no further lesions appearing during the course of the study. This example clearly illustrates the need for the second treatment cycle with imiquimod 3.75%, even if all of the AK lesions disappear after the first treatment cycle.³⁶ Overall, the two treatment cycles effectively eradicate a patient's clinical and subclinical AK lesions and so have the potential to substantially reduce the risk of subsequent progression to invasive SCC.

Acceptable tolerability and personalized treatment

Imiquimod 3.75% has an acceptable tolerability profile, and the short and simple treatment regimen is convenient for patients and associated with excellent compliance rates of over 95%.^{15,16} In particular, elderly patients may find the once-daily treatment regimen easier to adhere to than more frequent regimens.^{37,38} During treatment with imiquimod 3.75%, patients may experience local skin reactions, such as erythema, oedema, weeping, exudate, flaking, scaling, dryness, scabbing, crusting and erosion or ulceration.¹⁶ These local skin reactions may be considered as desirable effects rather than adverse events because they indicate that a localized immune response in the epidermis has begun and that imiquimod 3.75% is having a beneficial effect.⁷ Rest periods are allowed during imiquimod 3.75% treatment, with resumption of the treatment when the skin reactions have adequately resolved. The dosing period is not extended to compensate for missed doses during any rest period that is taken. These treatment interruptions are required in approximately one of every ten patients.¹⁶ The efficacy of imiquimod 3.75% is not affected if these rest periods are taken with a similar median percentage reduction in lesions from Lmax to the end of the 14-week studies in patients who did and did not take a rest period (90.0% and 92.3% respectively).³⁹

Conclusions

In conclusion, imiquimod 3.75% is the only AK treatment which can detect and clear clinical and subclinical lesions across an entire sun-exposed field, eradicating 92% of all AK lesions. Imiquimod 3.75% also offers dermatologists the opportunity to simply detect subclinical lesions and therefore to visualize the full burden of a patient's disease. Other benefits of imiquimod

3.75% are that it has an acceptable tolerability profile and has the advantage of being self-applied by the patient in two short treatment cycles each of 2 weeks' duration separated by a 2-week treatment-free interval. The treatment cycles can be personalized to allow rest periods from treatment, if necessary, to manage local skin reactions with no loss in efficacy. Together these factors lead to the vast majority of patients – over 95% – being compliant with the treatment regimen. The new Lmax concept also represents a significant advance in the evaluation of the efficacy of field-directed therapies because it takes into account the clearance of not only clinical lesions, but also subclinical lesions which become detectable during treatment.

Together, imiquimod 3.75% and the new Lmax concept set a new standard in the management of patients with AK.

Acknowledgement

Editorial assistance in the preparation of this manuscript was provided by David Harrison, Medscript Communications and was funded by Meda Pharma GmbH & Co. KG.

References

- 1 Stockfleth E. The paradigm shift in treating actinic keratosis: a comprehensive strategy. *J Drugs Dermatol* 2012; **11**: 1462–1467.
- 2 Berman B, Bienstock L, Kuritzky L, Mayeaux EJ Jr, Tyring SK. Actinic keratoses: sequelae and treatments. Recommendations from a consensus panel. *J Fam Pract* 2006; **55**(Suppl): 1–8.
- 3 Ibrahim SF, Brown MD. Actinic keratoses: a comprehensive update. *J Clin Aesthet Dermatol* 2009; **2**: 43–48.
- 4 Fenske NA, Spencer J, Adam F. Actinic keratoses: past, present and future. *J Drugs Dermatol* 2010; **9**: s45–s49.
- 5 Kennedy C, Bajdik CD, Willemze R, De Gruijl FR, Bouwes Bavinck JN. The influence of painful sunburns and lifetime sun exposure on the risk of actinic keratoses, seborrheic warts, melanocytic nevi, atypical nevi, and skin cancer. *J Invest Dermatol* 2003; **120**: 1087–1093.
- 6 Frost CA, Green AC, Williams GM. The prevalence and determinants of solar keratoses at a subtropical latitude (Queensland, Australia). *Br J Dermatol* 1998; **139**: 1033–1039.
- 7 Stockfleth E, Ortonne JP, Alomar A. Actinic keratosis and field cancerisation. *Eur J Dermatol* 2011; **21**(Suppl 1): 3–12.
- 8 Ulrich M, Krueger-Corcoran D, Roewert-Huber J, Sterry W, Stockfleth E, Astner S. Reflectance confocal microscopy for noninvasive monitoring of therapy and detection of subclinical actinic keratoses. *Dermatology* 2010; **220**: 15–24.
- 9 Ortonne JP, Gupta G, Ortonne N, Duteil L, Queille C, Malfefet P. Effectiveness of cross polarized light and fluorescence diagnosis for detection of sub-clinical and clinical actinic keratosis during imiquimod treatment. *Exp Dermatol* 2010; **19**: 641–647.
- 10 Green A, Battistutta D. Incidence and determinants of skin cancer in a high-risk Australian population. *Int J Cancer* 1990; **46**: 356–361.
- 11 Feldman SR, Fleischer AB Jr. Progression of actinic keratosis to squamous cell carcinoma revisited: clinical and treatment implications. *Cutis* 2011; **87**: 201–207.
- 12 Stockfleth E, Ferrandiz C, Grob JJ, Leigh I, Pehamberger H, Kerl H. Development of a treatment algorithm for actinic keratoses: a European Consensus. *Eur J Dermatol* 2008; **18**: 651–659.
- 13 Stockfleth E, Gupta G, Peris K, Aractingi S, Dakovic R, Alomar A. Reduction in lesions from Lmax: a new concept for assessing efficacy of field-directed therapy for actinic keratosis. Results with imiquimod 3.75%. *Eur J Dermatol* 2014; **24**: 23–27.

- 14 Gupta AK, Cooper EA, Abramovits W. Zyclara (imiquimod) cream, 3.75%. *Skinmed* 2010; **8**: 227–229.
- 15 Quist SR, Gollnick HP. Imiquimod 3.75% cream (Zyclara) for the treatment of actinic keratoses. *Expert Opin Pharmacother* 2011; **12**: 451–461.
- 16 Swanson N, Abramovits W, Berman B, Kulp J, Rigel DS, Levy S. Imiquimod 2.5% and 3.75% for the treatment of actinic keratoses: results of two placebo-controlled studies of daily application to the face and balding scalp for two 2-week cycles. *J Am Acad Dermatol* 2010; **62**: 582–590.
- 17 Swanson N, Smith CC, Kaur M, Goldenberg G. Imiquimod 2.5% and 3.75% for the treatment of actinic keratoses: two phase 3, multicenter, randomized, double-blind, placebo-controlled studies. *J Drugs Dermatol* 2014; **13**: 166–169.
- 18 Lebwohl M, Swanson N, Anderson LL, Melgaard A, Xu Z, Berman B. Ingenol mebutate gel for actinic keratosis. *N Engl J Med* 2012; **366**: 1010–1019.
- 19 Alomar A, Bichel J, McRae S. Vehicle-controlled, randomized, double-blind study to assess safety and efficacy of imiquimod 5% cream applied once daily 3 days per week in one or two courses of treatment of actinic keratoses on the head. *Br J Dermatol* 2007; **157**: 133–141.
- 20 Jorizzo J, Dinehart S, Matheson R *et al*. Vehicle-controlled, double-blind, randomized study of imiquimod 5% cream applied 3 days per week in one or two courses of treatment for actinic keratoses on the head. *J Am Acad Dermatol* 2007; **57**: 265–268.
- 21 Rivers JK, Arlette J, Shear N, Guenther L, Carey W, Poulin Y. Topical treatment of actinic keratoses with 3.0% diclofenac in 2.5% hyaluronan gel. *Br J Dermatol* 2002; **146**: 94–100.
- 22 Wolf JE Jr, Taylor JR, Tschen E, Kang S. Topical 3.0% diclofenac in 2.5% hyaluronan gel in the treatment of actinic keratoses. *Int J Dermatol* 2001; **40**: 709–713.
- 23 Krawtchenko N, Roewert-Huber J, Ulrich M, Mann I, Sterry W, Stockfleth E. A randomised study of topical 5% imiquimod vs. topical 5-fluorouracil vs. cryosurgery in immunocompetent patients with actinic keratoses: a comparison of clinical and histological outcomes including 1-year follow-up. *Br J Dermatol* 2007; **157**(Suppl 2): 34–40.
- 24 Gupta AK. The management of actinic keratoses in the United States with topical fluorouracil: a pharmaco-economic evaluation. *Cutis* 2002; **70**: 30–36.
- 25 Szeimies RM, Karrer S, Radakovic-Fijan S *et al*. Photodynamic therapy using topical methyl 5-aminolevulinic acid compared with cryotherapy for actinic keratosis: a prospective, randomized study. *J Am Acad Dermatol* 2002; **47**: 258–262.
- 26 Piacquadio DJ, Chen DM, Farber HF *et al*. Photodynamic therapy with aminolevulinic acid topical solution and visible blue light in the treatment of multiple actinic keratoses of the face and scalp: investigator-blinded, phase 3, multicenter trials. *Arch Dermatol* 2004; **140**: 41–46.
- 27 Gaspari AA. Mechanism of action and other potential roles of an immune response modifier. *Cutis* 2007; **79**: 36–45.
- 28 Sauder DN. Immunomodulatory and pharmacologic properties of imiquimod. *J Am Acad Dermatol* 2000; **43**: S6–S11.
- 29 Lacarrubba F, Nasca MR, Micali G. Advances in the use of topical imiquimod to treat dermatologic disorders. *Ther Clin Risk Manag* 2008; **4**: 87–97.
- 30 Schiller M, Metzke D, Luger TA, Grabbe S, Gunzer M. Immune response modifiers—mode of action. *Exp Dermatol* 2006; **15**: 331–341.
- 31 Schon M, Bong AB, Drewniok C *et al*. Tumor-selective induction of apoptosis and the small-molecule immune response modifier imiquimod. *J Natl Cancer Inst* 2003; **95**: 1138–1149.
- 32 Torres A, Storey L, Anders M *et al*. Immune-mediated changes in actinic keratosis following topical treatment with imiquimod 5% cream. *J Transl Med* 2007; **5**: 7.
- 33 Stockfleth E. Long-term sustained lesion clearance from Lmax with imiquimod 3.75%, a new field-directed treatment for actinic keratosis. Poster presented at EADV 2013 Abstract P0384.
- 34 Hanke CW, Swanson N, Bruce S, Berman B, Kulp J, Levy S. Complete clearance is sustained for at least 12 months after treatment of actinic keratoses of the face or balding scalp via daily dosing with imiquimod 3.75% or 2.5% cream. *J Drugs Dermatol* 2011; **10**: 165–170.
- 35 Gupta G. Imiquimod 3.75% and risk of progression to squamous cell carcinoma from actinic keratosis: case studies of potential benefit. Poster presented at EADV 2012 Abstract P0504.
- 36 Gupta G. Effective clearance of actinic keratosis with imiquimod 3.75%: case study confirming the need for repeat immune stimulation with two treatment cycles. Poster presented at EADV 2012 Abstract P0503.
- 37 Werschler WP. Considerations for use of Fluorouracil cream 0.5% for the treatment of actinic keratosis in elderly patients. *J Clin Aesthet Dermatol* 2008; **1**: 22–27.
- 38 Claesson S, Morrison A, Wertheimer AI, Berger ML. Compliance with prescribed drugs: challenges for the elderly population. *Pharm World Sci* 1999; **21**: 256–259.
- 39 Alomar A. Efficacy of imiquimod 3.75% from Lmax in patients with and without rest periods during treatment. Poster presented at EADV 2013 Abstract P0536.